




ORIGINAL ARTICLE

Treating facial overfilled syndrome with impaired facial expression—Presenting clinical experience with ultrasound imaging

Leonie Schelke MD, PhD¹  | Steven Harris MBBCh, MSc² | Hugues Cartier MD³ | Michael Alfertshofer MD⁴  | Marwah Doestzada MD⁵ | Sebastian Cotofana PhD^{1,6}  | Peter J. Velthuis MD, PhD¹

¹Department of Dermatology, Erasmus University Medical Center, Rotterdam, The Netherlands

²Harris Clinic, Crouch Hall Road Surgery, London, UK

³Clinic of Dermatology, Arras, France

⁴Division of Hand, Plastic and Aesthetic Surgery, Ludwig-Maximilians-University Munich, Munich, Germany

⁵Aestec, Amsterdam, The Netherlands

⁶Centre for Cutaneous Research, Blizard Institute, Queen Mary University of London, London, UK

Correspondence

Sebastian Cotofana MD, PhD, PhD, Department of Dermatology, Erasmus Medical Center, Dr. Molewaterplein 40, 3015 GD Rotterdam, The Netherlands. Email: scotofana24@gmail.com

[Correction added on 9 October 2023 after first online publication: The second author's name and degree have been updated and the 5th affiliation has been updated in this version.]

Abstract

Background: Facial overfilled syndrome is an adverse event following minimally invasive soft tissue filler injections. It presents in most cases as excess midfacial volume and/or as unnatural smile which is difficult to detect due to the absence of standardized evaluation methods.

Objective: To showcase how to identify, evaluate, and treat facial overfilled syndrome by utilizing facial ultrasound and simultaneous hyaluronidase injections.

Methods: Twenty-eight consecutive patients (26 females, 2 males) were enrolled in this study in which facial ultrasound was performed to evaluate the location previously implanted filler material. The position of the oral commissure was objectively measured in relation to bony landmarks, and the severity of lateral canthal lines was assessed by independent and blinded raters.

Results: The material was identified in 35.7% inside the subdermal fatty layer, in 28.6% inside the deep supra-periosteal fatty layer, in 10.7% inside the fibrous layer deep to the subdermal fatty layer, whereas in 25.0%, the product was not possible to locate clearly inside one specific layer. On average, 81.6 I.U. [range: 75–150] of hyaluronidase were injected. Lateral canthal line severity was before the treatment 2.28 (1.4) and was after the hyaluronidase treatment 2.02 (1.3) with $p = 0.578$. The position of the oral commissure increased by 0.60 cm in vertical and by 0.30 cm in horizontal directions (both $p < 0.001$).

Conclusion: Facial overfilled syndrome following aesthetic soft tissue filler injections can present as excess midfacial volume but also as unnatural smile. Targeted hyaluronidase injections into the culprit pockets inside the midfacial soft tissues have shown to re-establish a natural smile, to reduce excess midfacial volume, and to decrease lateral canthal line severity.

Sebastian Cotofana and Peter J. Velthuis contributed equally to this work.

This is an open access article under the terms of the [Creative Commons Attribution](https://creativecommons.org/licenses/by/4.0/) License, which permits use, distribution and reproduction in any medium, provided the original work is properly cited.

© 2023 The Authors. *Journal of Cosmetic Dermatology* published by Wiley Periodicals LLC.

KEYWORDS

facial anatomy, facial overfilled syndrome, facial ultrasound, hyaluronidase, soft tissue fillers

1 | INTRODUCTION

Minimally invasive soft tissue filler treatments to ameliorate the signs of facial aging or for enhancing individual beauty are increasing in popularity and acceptance worldwide.^{1,2} Almost every facial region is targeted including lips,^{3,4} temples,^{5,6} jawline,^{7,8} nose,^{9,10} and cheek^{11,12} with great effectiveness. Concomitantly, the advancements in aesthetic research have progressed increasing the knowledge about filler rheology, product-tissue interactions, and facial anatomy especially for the purposes of increasing safety and improving treatment outcomes.¹³⁻¹⁶

Recently, a group of researchers was able to identify the underlying anatomy behind the facial overfilled syndrome, a posttreatment appearance which leads to an unbalanced alteration of the functional facial anatomy at rest and during facial expression. Patients experience high-volume cheeks at rest, unnatural smile, depressed temples, and reduced peri-oral mobility. This syndrome might be due to overfilling of the facial compartments but also due to inappropriate filler placement. Not all factors need to be included for the overfilled syndrome; in this study, we mainly focus on the unnatural smile. The researchers described for the first time in the literature an anatomic structure in the middle face which was termed *transverse facial septum*, and which was connected to the undersurface of the zygomaticus major muscle, and which formed the inferior boundary of the superficial and of the deep fat compartments. Together with the midfacial superficial musculoaponeurotic system (SMAS), the transverse facial septum was described to be crucial for natural

facial expressions and for the physiologic movement of both the superficial and deep fat compartments.¹⁷

The latter compartments are the major target for minimally invasive cheek volumizing procedures utilizing soft tissue fillers.^{13,18} It is plausible that the administration of excess filler product in the midface can influence the physiologic mobility of the midfacial soft tissues by increasing the local volume and by thus affecting the normal movements of the transverse facial septum, the zygomaticus major muscle, and of the midfacial SMAS. (Figures 1,2) Patients suffering from facial overfilled syndrome may not realize symptoms at all or may complain about an unnatural smile only. Physicians need to be aware of such signs and should be able to diagnose and treat accordingly.

The objective of this study is to showcase the treatment algorithm of patients affected by the facial overfilled syndrome by utilizing facial ultrasound and hyaluronidase administrations.

2 | METHODS

2.1 | Study sample

Patients included in this retrospective cohort study were consecutive patients of the authors of the study from the Department of Dermatology, Erasmus University Medical Center, Rotterdam, The Netherlands and from Harris Clinic, Crouch Hall Road Surgery, London, United Kingdom.

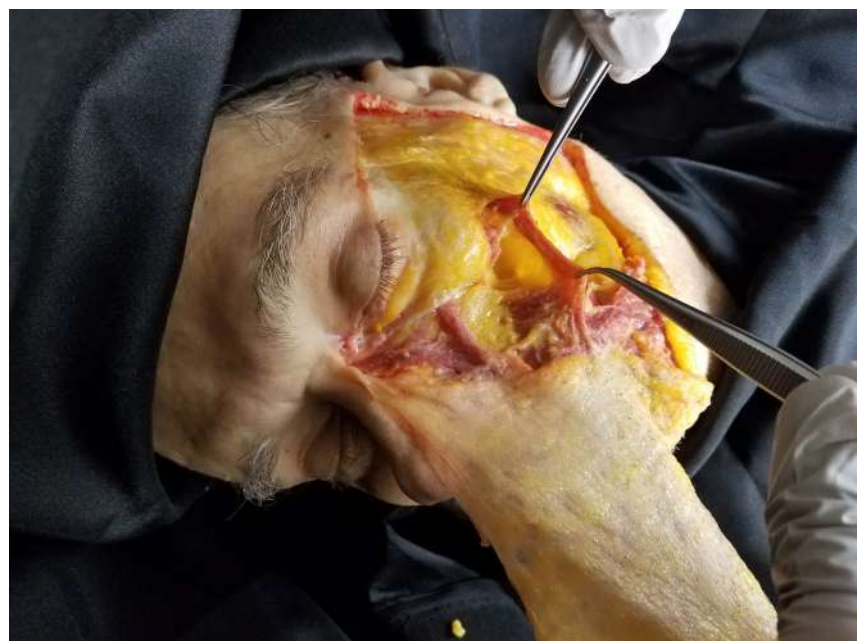

FIGURE 1 Cadaveric dissection demonstrating the transverse facial septum and its relationship to the zygomaticus major muscle.

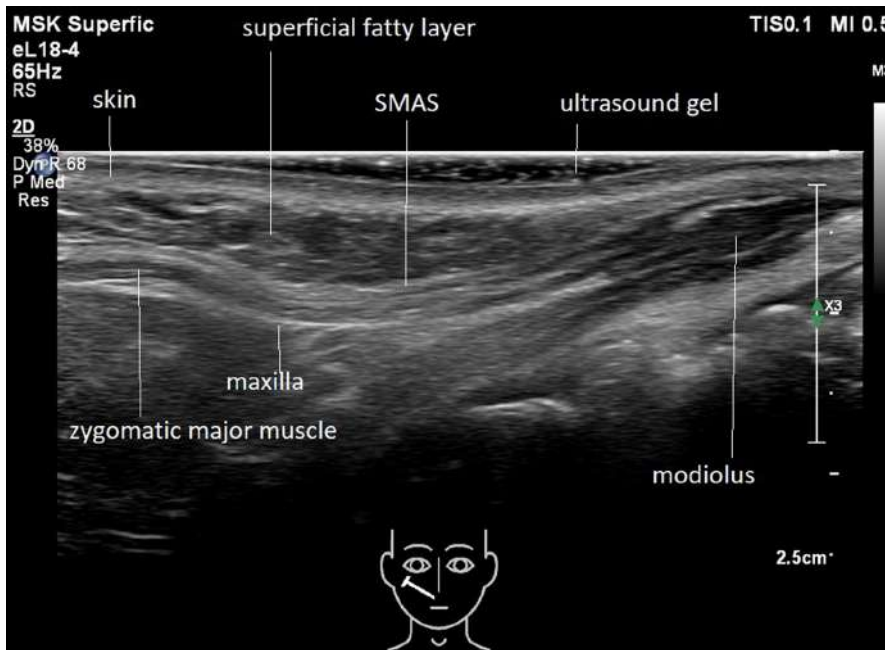


FIGURE 2 Ultrasound image showing the anatomy of the midface, especially the relationship between the zygomaticus major muscle and the midfacial superficial musculoaponeurotic system (SMAS).

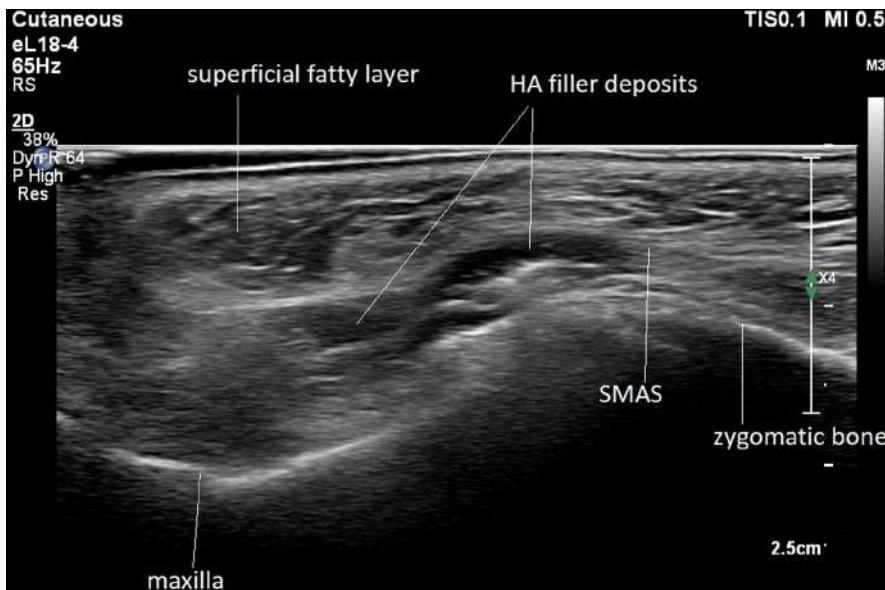


FIGURE 3 Ultrasound image showing the horizontal scan of the midface as indicated in the overview. The hyaluronic acid-based filler material is visible (HA) inside the fibrous layer closely related to the zygomaticus major muscle between the superficial and the deep fatty layers.

Patients were enrolled in this study if they complained about an unnatural smile and/or an unnaturally increased midfacial volume following a previous aesthetic soft tissue filler injection. Patients with potential signs of inflammation (redness, pain, granuloma formation) were not included in this analysis due to a different origin of their symptoms which is not facial overfilled syndrome.

All patients included in this study provided written informed consent for accessing their data for the purposes of this study. All treatments were performed in accordance with the standards of good clinical care following local guidelines and regulations. Ethics committee approval to gather data concerning soft tissue filler complications was obtained (MEC-2016-0660); ultrasound imaging is considered the gold standard of care for the management of adverse events according to The Medical Research Involving Human Subjects Act.

2.2 | Clinical assessment

2.2.1 | Ultrasound imaging

Following initial patient consult, facial ultrasound was conducted to identify and document the location of the previously performed filler injection. (Figures 3–5) Ultrasound operators were experienced in facial ultrasound anatomy and filler recognition. The device utilized was a high-frequency MHz probe (Philips Affinity 70, 18 MHz and 20-MHz linear probe GE Healthcare Venue Go).

Following ultrasound-based facial assessment, the filler material was targeted with hyaluronidase (Hyason®) under simultaneous ultrasound imaging to increase precision during the dissolving procedure.

FIGURE 4 Ultrasound imaging showing the hyaluronic acid-based filler material in close topographical relationship to the superficial musculoaponeurotic system (SMAS) between the superficial and the deep fatty layer.

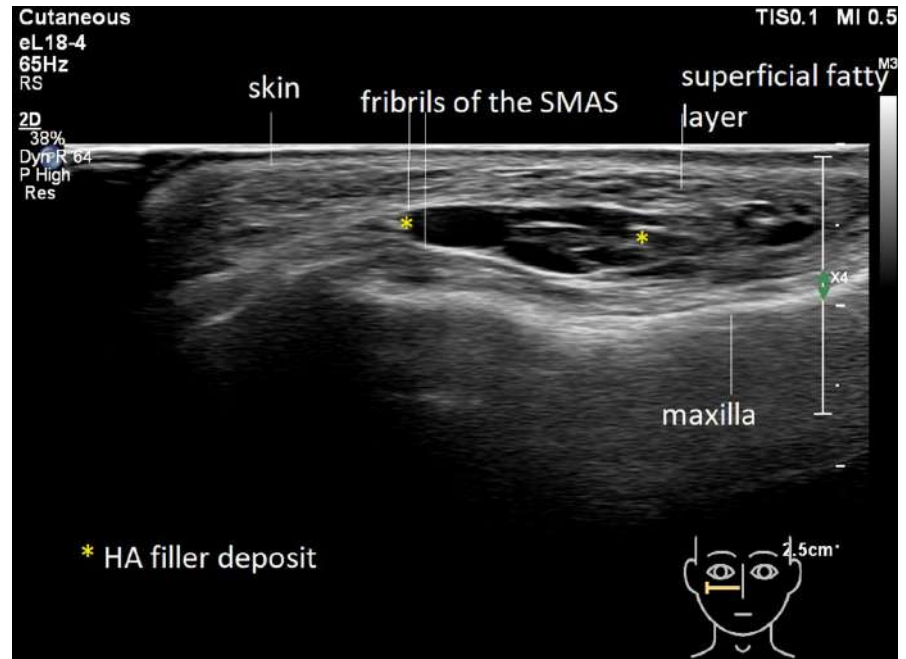
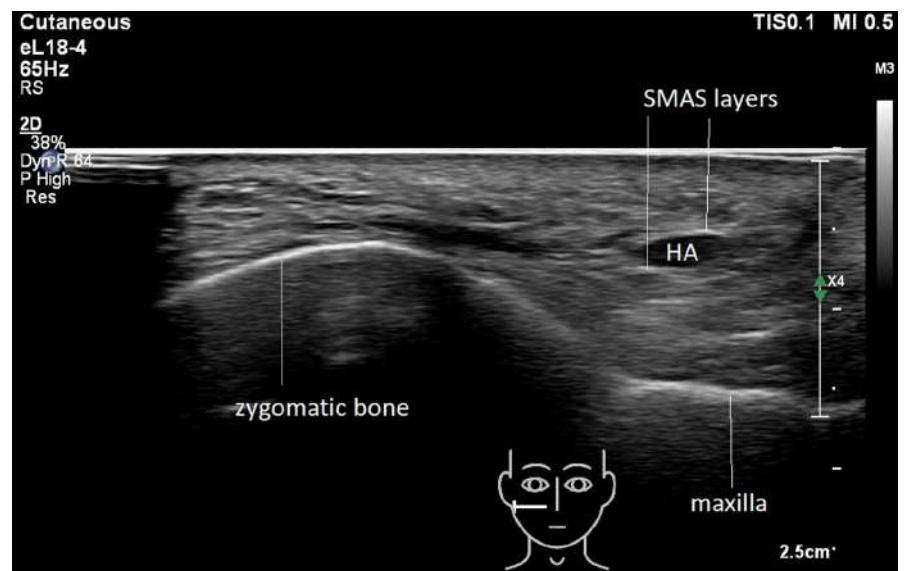


FIGURE 5 Ultrasound imaging showing the hyaluronic acid-based filler material in close topographical relationship to the superficial musculoaponeurotic system (SMAS).



2.2.2 | Smile evaluation

To objectively evaluate the amplitude of the smile of the enrolled patients, the position of the oral commissure of the affected facial side was investigated. The distance of the corner of the mouth to the bony jawline and to the nasal spine before and after filler removal was measured, at rest and during maximal smiling (Duchenne-type smiling) following a standardized protocol:

1. A vertical line from the oral commissure to the bony jawline at rest (not smiling) was marked at the bony jawline, and the vertical distance between position of oral commissure and the jawline was measured; this measurement was regarded as the vertical position of the oral commissure (Figure 6).

2. A horizontal line connecting the skin projection of the nasal spine was drawn and connected to a vertical line passing through the oral commissure; this measurement was regarded as the horizontal position of the oral commissure (Figure 7).

Both measurements (1 and 2) were conducted before and immediately after the treatment with hyaluronidase.

2.2.3 | Wrinkle scale evaluation

A photo numeric 5-point Likert scale (0–4; best to worst) for the assessment of the lateral canthal lines was used to assess the crow feet's before and after the treatment with hyaluronidase.¹⁹

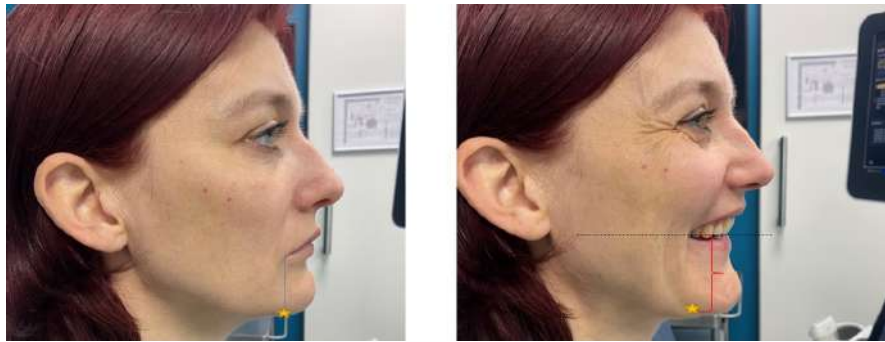

FIGURE 6 Photograph illustrating the measurement of the vertical distance between the oral commissure and the jawline, in a repose and smiling facial expression.

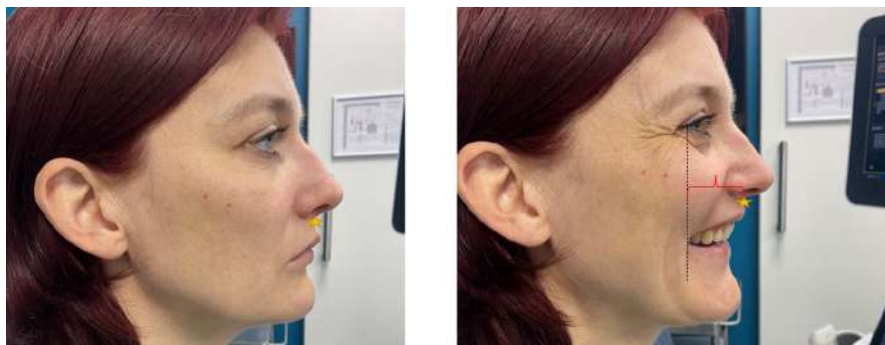

FIGURE 7 Photograph illustrating the measurement of the horizontal distance between the skin projection of the nasal spine and the vertical line passing through the oral commissure, in a repose and smiling facial expression.

Assessment was done based on patient 2D images and was performed online by three experienced physicians blinded to the sequence of treatment (PV, SC, HC).

2.2.4 | Analytic procedure

The purpose of this study was to investigate the effects of hyaluronidase treatment on the position of the oral commissure and on the severity of lateral canthal lines in patients presenting with facial overfilled syndrome. Additionally, the natural appearance of the smile was assessed by the patients and by the treating physician. Given the fact that no scale is currently available for the assessment of a natural smile, the outcome of the hyaluronidase treatment was graded dichotomously in terms of improved (yes) and not improved (no).

Comparative statistical testing was conducted as paired sample *t*-test to compare the position of the oral commissure before and after the treatment as well as to compare the severity of lateral canthal lines. Statistical analysis was conducted with IBM SPSS Statistics 25, and a two-tailed *p*-value of ≤ 0.05 was chosen to guide statistical significance.

3 | RESULTS

3.1 | Sample description

The investigated sample consisted of 28 consecutive patients, of which 26 were females and 2 males resulting in a total of $n=56$ evaluated facial sides. The mean age was 45.8 (9.7) [range: 30–63] years

with a Fitzpatrick classification of: I $n=8$, II $n=10$, III $n=8$, IV $n=1$, V $n=1$, respectively. Their initial aesthetic treatment, in which the initial soft tissue filler implantation occurred, was 21.7 (28.3) [range: 1–132] months prior to their inclusion into this investigation.

3.2 | Patient evaluation

Patients complained in $n=34$ (out of 56 possible facial sides; 60.7%) about their unnatural smile, whereas in $n=21$ (37.5%) their complaint was related to an over-volumized cheek, and in $n=1$ (1.8%) nodules were perceived in their midface following the initial aesthetic treatment. The onset of their complains started in $n=41$ (83.7%) immediately after the initial aesthetic treatment, whereas in $n=4$ (8.2%) it started weeks and in $n=4$ (8.2%) it started months after the initial treatment (accuracy of data capture was based on patient self-reporting).

3.3 | Ultrasound examination

Upon ultrasound assessment, the initially injected soft tissue filler material was identified in all treated patients ($n=28$, 100%) inside the fibrous layer located between the superficial and deep fatty layers. In $n=20$ (out of 56; 35.7%) filler material was found additionally inside the subdermal fatty layer, in $n=16$ (28.6%) additionally inside the deep supra-periosteal fatty layer, in $n=6$ (10.7%) the product was found exclusively inside the fibrous layer deep to the subdermal fatty layer, whereas in $n=14$ (25.0%) the product was not possible to relate to a specific layer but was distributed across the entire midface. (Figure 1).

3.4 | Intervention

Under ultrasound guidance, hyaluronidase was administered into the visible hyaluronic acid pockets within each respective layer; this was performed in $n=40$ (71.4%) with a 25G cannula, whereas in $n=16$ (28.6%) a 27G needle was used independent of the layer where the product was located. In $n=9$ (32.1%) a second treatment session was needed.

On average, 81.61.U. (20.3) [range: 75–150] of hyaluronidase were administered under simultaneous ultrasound visualization (Figure 7).

3.5 | Outcome

In $n=56$ (100%) of the treated facial sides, an immediate improvement was noted following the hyaluronidase administration. This was testified by the patients immediately after the treatment and confirmed by the treating physician.

Lateral canthal line severity as assessed on a scale 0–4 (best to worst) and was before the treatment (when assessed by three independent and blinded raters based on online 2D images during Duchenne-type smiling) 2.28 (1.4) and was after the hyaluronidase treatment 2.02 (1.3) with $p=0.018$.

The position of the oral commissure during Duchenne-type smiling was before the treatment (vertical vs. horizontal coordinates) 4.31 (0.4)cm versus 4.11 (0.4)cm, whereas after the treatment the position was 4.91 (0.4)cm versus 4.41 (0.4)cm with $p<0.001$ for both measurements (Figures 8–11).

4 | DISCUSSION

This observational cohort study investigated in 28 consecutive patients the outcome following ultrasound-guided midfacial hyaluronidase treatments for facial overfilled syndrome. The facial overfilled syndrome presented in this cohort in 60.7% of the cases as having an unnatural smile (as perceived by the patient), in 37.5% of the cases

as over-volumized cheeks (as perceived by the patient and evaluated by the treating physician), and in 1.8% of the cases with subcutaneous nodules (as evaluated by the treating physician). Patients were treated initially for medial and lateral midfacial volumization with hyaluronic acid-based soft tissue fillers and started to notice symptoms in 83.7% immediately after their initial aesthetic treatment, in 8.2% after weeks, and in 8.2% months following their initial filler implantation. Following the patient's intent to resolve the signs of the overfilled syndrome, patients were clinically evaluated and examined via facial ultrasound imaging and treated with hyaluronidase under simultaneous ultrasound guidance. The treatment was conducted until immediate improvement was achieved which required on average 81.61.U. [range: 75–150] of hyaluronidase in the cohort investigated.

It must be noted that the accuracy of data regarding the initial aesthetic treatment of the 28 included patients is reduced due to the limited availability of information provided by the patient during their initial consult and due to the absence of a patient documentary chart; all treated patients were referred patients. Therefore, detailed information about the precise layer of initial filler implantation, amount of filler injected, specific injection technique (needle or cannula), or about the type of filler utilized is incomplete and must be regarded as a limitation of this investigation. To work around the missing information, a detailed facial ultrasound examination was conducted at the first patient consult and the location (2D), layer (3D), and the approximate amount of midfacial filler was documented. This step helped to identify whether the product is amenable for hyaluronidase injections as biostimulator products (like calcium hydroxyl apatite) might not dissolve when targeted as their presentation in ultrasound imaging is different: hypo-echoic (black) pockets for hyaluronic acid-based product versus hyper-echoic (white) pockets or lines for calcium hydroxyl apatite products.

Once patients were evaluated and the diagnosis facial overfilled syndrome was confirmed, the hyaluronic acid-based filler material was targeted via simultaneous ultrasound-guided injection with hyaluronidase. Once treatment was completed, it was noted that the volume of the medial and lateral midface was reduced and that the natural appearance of the smile was restored which was confirmed

FIGURE 8 Ultrasound image showing the oblique scan of the midface as indicated in the overview. The hyaluronic acid-based filler material is visible (HA) inside the fibrous layer closely related to the zygomaticus major muscle between the superficial and the deep fatty layers. The cannula is visible during the application of hyaluronidase.

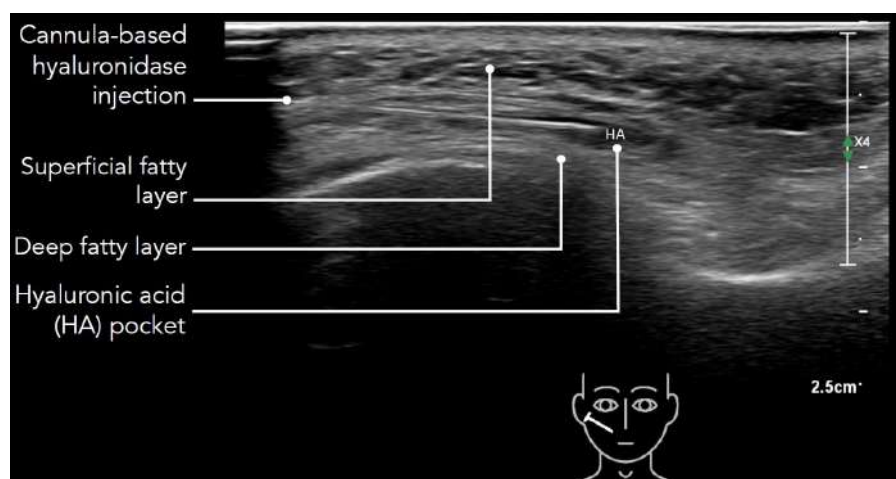

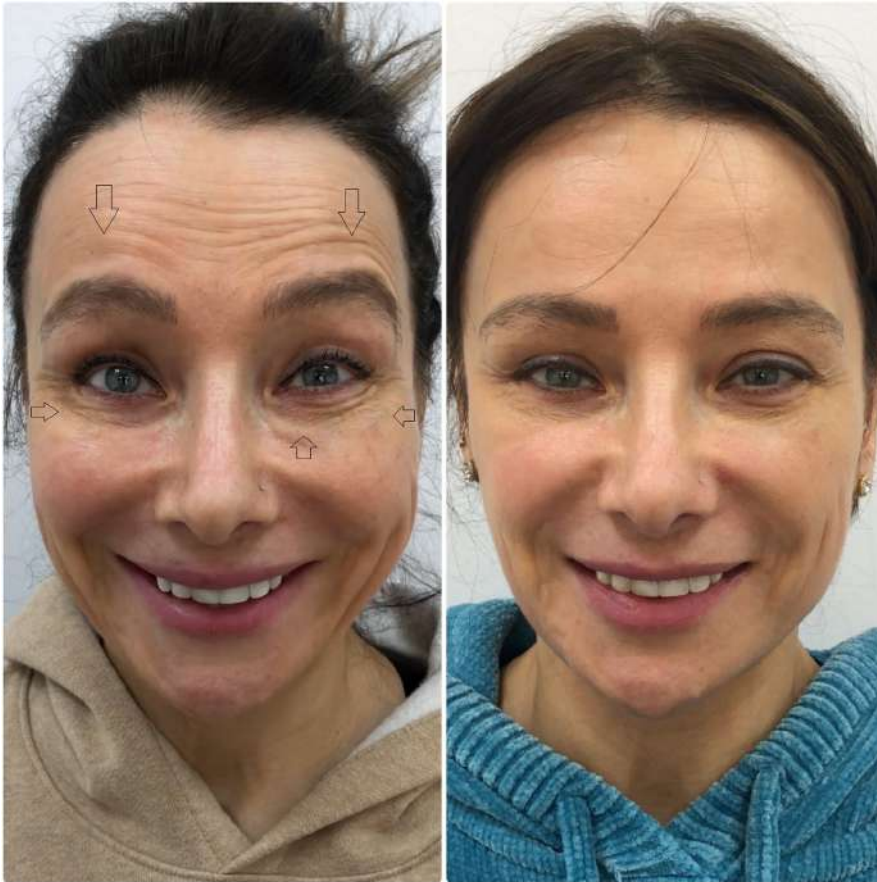


FIGURE 9 Clinical image of a smiling female patient before (left panel) versus after (right panel) the treatment of ultrasound-guided hyaluronidase injection to the midface.

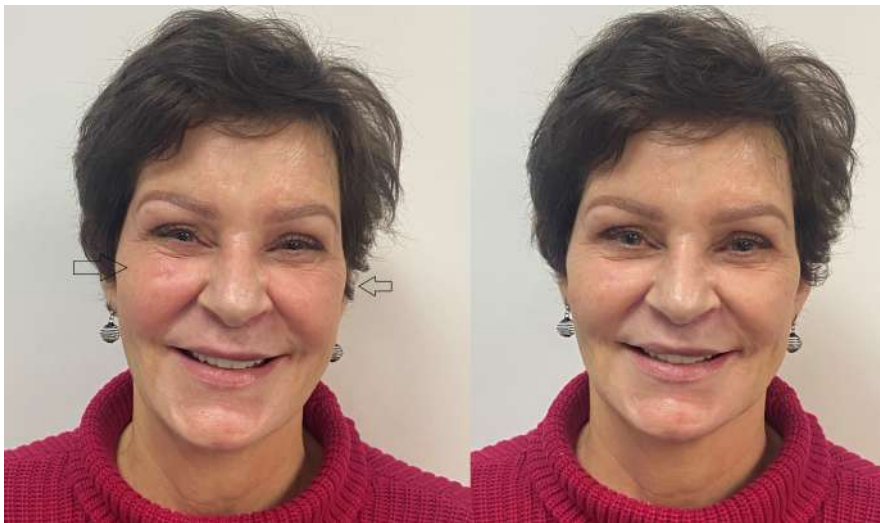
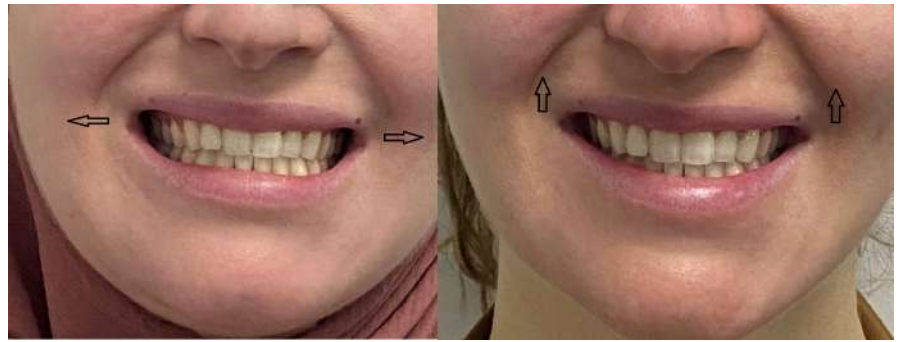
FIGURE 10 Clinical image of a smiling female patient before (left panel) versus after (right panel) the treatment of ultrasound-guided hyaluronidase injection to the midface.

both by the patient and by the treating physician in 100% of the cases. The additionally conducted measurements for the position of the oral commissure during Duchenne-type smiling after the treatment with hyaluronidase increased by 0.60cm in vertical and by 0.30cm in horizontal directions (both $p < 0.001$) when related to the bony jawline and to the skin projection of the nasal spine, respectively. This change in smile toward a wider, more open, and more elevated smile can be explained anatomically: the zygomatic major muscle is the facial muscle predominantly responsible for smiling. The muscle originates deep from the zygomatic arch and inserts

superficially into the modiolus. Along its 3D course (from deep to superficial), the muscle is embedded inside the midfacial SMAS and contributes to the movement of both the superficial fatty layer and of the midface SMAS.^{13,14,20} Having excess filler material inside the superficial fatty layer or inside the fibrous layer deep to the superficial fatty layer might have resulted in the limited ability of the muscle to pull the modiolus and thus the oral commissure vertical and horizontal toward the zygomatic arch; this seems to have resulted in the patient's perception of an unnatural smile. As the filler deposits inside the fibrous layers were often single and limited in volume, we

FIGURE 11 Clinical image of a smiling female patient before (left panel) versus after (right panel) the treatment of ultrasound-guided hyaluronidase injection to the midface.



assume that the presence of fillers may act as a hindrance to movement. By removing the filler material with targeted hyaluronidase injections, the mobility of the oral commissure was restored, and the mobility increased when tested during Duchenne-type smiling.

Additionally, it was observed that the severity of lateral canthal lines improved following treatment with hyaluronidase, when assessed on 2D photographs by three independent readers which were blinded to the sequence of treatment. Before the treatment, the severity score was 2.28 compared to 2.02 after the treatment, despite no other aesthetic treatment was conducted. This effect can be explained as follows: Duchenne-type smiling includes the additional contraction of orbicularis oculi muscle in support of zygomatics major muscle. Having excess filler material in the superficial or deep midfacial fat compartments or within the fibrous layer in-between would result in more workload for both muscles to affect facial expressions; this could be most likely observed by an increased severity of lateral canthal lines. Reducing the amount of filler product within the fatty layers or within the fibrous layer between them (SMAS, transverse facial septum) might have reduced the need for excess contraction in both muscles resulting in a lesser contractility of the orbicularis oculi muscles with consecutive reduction in lateral canthal line severity. The removal of midfacial filler material would reduce the need for the orbicularis oculi muscle to contract excessively during Duchenne-type smiling which might be the reason why the scores of lateral canthal line severity reduced from 2.28 to 2.02.

Another effect, following the hyaluronidase treatment was the immediate reduction in midfacial volume during Duchenne-type smiling. This is plausible from an anatomic point of view: deep to the zygomaticus major muscle, the transverse facial septum can be identified. This septum connects the muscle to the underlying maxilla and forms the inferior boundary of the superficial and deep midfacial fat compartments.¹⁷ Having excess filler material inside either of those compartments would result in excess midfacial volume which was perceived by the patients in 37.5% of the cases as over-volumized cheeks when evaluated by the patient and by the treating physician. Removing the excess filler product from the superficial fatty layer, or from the deep fatty layer, or from the fibrous layer in-between, midfacial SMAS or transverse facial septum resulted in immediate reduction in midfacial volume in this cohort. This was classified as an 100% improvement both by the treated patient and by the injecting physician.

The performed outcome evaluations were based on the perception of the patient and of the treating physician, rather than on a validated scoring system; this needs to be regarded as a major limitation of this study.²¹ However, this was done due to the lack of a scale that provides guidance for midfacial volume evaluation during smiling or during active facial expressions; most scales evaluate facial volume at rest rather than during smiling. The procedures performed reflect daily clinical activities for many injectors worldwide. It is hoped that the algorithm showcased in this study will help and guide practitioners on how to recognize a facial overfilled syndrome and how to use ultrasound guidance to specifically target the culprit material without affecting midfacial soft tissues by hyaluronidase. It has to be noted that hyaluronidase can also affect other midfacial soft tissues due to its unspecified affinity to the extra-cellular matrix of any tissue. This effect was limited in this study by using ultrasound-guided injections which targeted the filler deposits exclusively.

5 | CONCLUSION

Facial overfilled syndrome following aesthetic soft tissue filler injections can present as excess midfacial volume but also as unnatural smile. This is the first study of its kind to bring attention to an impaired facial expression that requires detailed patient consult and facial ultrasound scanning to be identified. Targeted hyaluronidase injections into the culprit pockets inside the midfacial soft tissues have shown to re-establish a natural smile, to reduce excess midfacial volume, and to decrease lateral canthal line severity. All beneficial treatment effects can be explained following a deep understanding of facial biomechanics and facial anatomy.

AUTHOR CONTRIBUTIONS

L.S., S.H., H.C., and P.J.V. performed the data acquisition. S.C., M.A., L.S., M.D., and P.J.V. designed the research study. L.S., M.A., and S.C. analyzed the data. S.C., M.A., L.S., S.H., and M.D. wrote the paper.

CONFLICT OF INTEREST STATEMENT

Dr. Schelke and Dr. Velthuis are shareholders in Cutaneous BV, a company that provides educational courses and materials in the realm of facial ultrasound imaging. None of the other authors have any conflict of interest with respect to the research, authorship, and publication of this article.

DATA AVAILABILITY STATEMENT

The data that support the findings of this study are available from the corresponding author upon reasonable request.

ETHICS STATEMENT

Authors declare human ethics approval was not needed for this study.

ORCID

Leonie Schelke  <https://orcid.org/0000-0002-5512-1956>

Michael Alfertshofer  <https://orcid.org/0000-0002-4892-2376>

Sebastian Cotofana  <https://orcid.org/0000-0001-7210-6566>

REFERENCES

- Cassuto D, Bellia G, Schiraldi C. An overview of soft tissue fillers for cosmetic dermatology: from filling to regenerative medicine. *Clin Cosmet Invest Dermatol*. 2021;14:1857-1866. doi:10.2147/CCID.S276676
- International Society of Aesthetic Plastic Surgeons (ISAPS). ISAPS International Survey on Aesthetic/Cosmetic Procedures Performed in 2020. Published online 2020:1-16.
- Cooper H, Gray T, Fronck L, Witfill K. Lip augmentation with hyaluronic acid fillers: a review of considerations and techniques. *J Drugs Dermatol*. 2023;22(1):23-29. doi:10.36849/JDD.6304
- Czumbel LM, Farkasdi S, Gede N, et al. Hyaluronic acid is an effective dermal filler for lip augmentation: a meta-analysis. *Front Surg*. 2021;8:681028. doi:10.3389/fsurg.2021.681028
- Cotofana S, Gaete A, Hernandez CA, et al. The six different injection techniques for the temple relevant for soft tissue filler augmentation procedures—clinical anatomy and danger zones. *J Cosmet Dermatol*. 2020;19:1570-1579. doi:10.1111/jocd.13491
- Carruthers J, Humphrey S, Beleznyay K, Carruthers A. Suggested injection zone for soft tissue fillers in the temple? *Dermatol Surg*. 2017;43(5):756-757. doi:10.1097/DSS.0000000000001057
- Go BC, Frost AS, Friedman O. Using injectable fillers for chin and jawline rejuvenation. *World J Otorhinolaryngol Head Neck Surg*. 2023;9(2):131-137. doi:10.1002/wjo2.93
- Rauso R, Rugge L, Chirico F, et al. Nonsurgical reshaping of the lower jaw with hyaluronic acid fillers: a retrospective case series. *Dermatol Pract Concept*. 2022;12(3):e2022095. doi:10.5826/dpc.1203a95
- Humphrey CD, Arkins JP, Dayan SH. Soft tissue fillers in the nose. *Aesthetic Surg J*. 2009;29(6):477-484. doi:10.1016/j.asj.2009.09.002
- Kurkjian TJ, Ahmad J, Rohrich RJ. Soft-tissue fillers in rhinoplasty. *Plast Reconstr Surg*. 2014;133(2):121e-126e. doi:10.1097/01.prs.0000437246.61294.33
- Lipko-Godlewska S, Bolanča Ž, Kalinová L, et al. Whole-face approach with hyaluronic acid fillers. *Clin Cosmet Invest Dermatol*. 2021;14:169-178. doi:10.2147/CCID.S292501
- Trinh LN, Gupta A. Non-hyaluronic acid fillers for midface augmentation: a systematic review. *Facial Plast Surg*. 2021;37(4):536-542. doi:10.1055/s-0041-1725164
- Cotofana S, Gotkin RH, Frank K, et al. The functional anatomy of the deep facial fat compartments—a detailed imaging based investigation. *Plast Reconstr Surg*. 2019;143(1):53-63. doi:10.1097/PRS.0000000000005080
- Schenck TL, Koban KC, Schlattau A, et al. The functional anatomy of the superficial fat compartments of the face: a detailed imaging study. *Plast Reconstr Surg*. 2018;141(6):1351-1359. doi:10.1097/PRS.0000000000004364
- Fundarò SP, Salti G, Malgapo DMH, Innocenti S. The rheology and physicochemical characteristics of hyaluronic acid fillers: their clinical implications. *Int J Mol Sci*. 2022;23(18):10518. doi:10.3390/ijms231810518
- Freytag L, Alfertshofer MG, Frank K, et al. Understanding facial aging through facial biomechanics: a clinically applicable guide for improved outcomes. *Facial Plast Surg Clin North Am*. 2022;30(2):125-133. doi:10.1016/j.fsc.2022.01.001
- Cotofana S, Gotkin RH, Frank K, Lachman N, Schenck TL. Anatomy behind the facial overfilled syndrome: the transverse facial septum. *Dermatol Surg*. 2019;46:e16-e22. doi:10.1097/DSS.0000000000002236
- Kapoor KM, Saputra DI, Porter CE, et al. Treating aging changes of facial anatomical layers with hyaluronic acid fillers. *Clin Cosmet Invest Dermatol*. 2021;14:1105-1118. doi:10.2147/CCID.S294812
- Carruthers A, Carruthers J, Hardas B, et al. A validated grading scale for crow's feet. *Dermatologic Surg*. 2008;34:S173-S178. doi:10.1111/j.1524-4725.2008.34367.x
- Broughton M, Fyfe GM. The superficial musculoaponeurotic system of the face: a model explored. *Anat Res Int*. 2013;2013:794682. doi:10.1155/2013/794682
- Sadeghi P, Ma W, Davita TR. The subjective and objective aspects of beauty standards in aesthetic plastic surgery: from the divine proportion to graceful aging. *Aesthetic Plast Surg*. 2022;46(6):3108-3110. doi:10.1007/s00266-022-02892-w

How to cite this article: Schelke L, Harris S, Cartier H, et al. Treating facial overfilled syndrome with impaired facial expression—Presenting clinical experience with ultrasound imaging. *J Cosmet Dermatol*. 2023;22:3252-3260. doi:10.1111/jocd.16013